

The Dental Learning Network



Local Anesthetic Review

8 Homestudy Credit Hours

Anthony S. Mennito, D.M.D.

**The Dental Learning Network
is a recognized ADA CERP provider**

Local Anesthetic Review

(8 Credit Hours - \$66.00)

Please mark your answers to the course exam below, then fax this page to 703-935-2190 for scoring and certificate issuance. Or, if you wish to receive your certificate immediately, [click here](#) to take this exam online. Payment will be accepted at the time you submit the exam for scoring. If you've already paid for this course and wish to take the exam online, but you don't have a user name and password, send an email request to **CESupport@DentalLearning.Org**.

- | | | | | |
|----------|-----------|-----------|-----------|-----------|
| 1. _____ | 6. _____ | 11. _____ | 16. _____ | 21. _____ |
| 2. _____ | 7. _____ | 12. _____ | 17. _____ | 22. _____ |
| 3. _____ | 8. _____ | 13. _____ | 18. _____ | 23. _____ |
| 4. _____ | 9. _____ | 14. _____ | 19. _____ | 24. _____ |
| 5. _____ | 10. _____ | 15. _____ | 20. _____ | 25. _____ |

Name: _____
D.D.S. D.M.D. R.D.H. R.D.A. C.D.A. C.O.A. D.A. A.Q.P.

License State: _____ **License Number:** _____ **Expiration Date** _____ (MM/YY)

Address 1: _____

Address 2: _____

City: _____ **State:** _____ **Zip Code:** _____

Telephone Number: _____ **Fax Number:** _____

E-mail: _____

Please help us improve:

Ordering experience was convenient:

yes no

I received my workbook or file in a timely manner:

yes no

Course text and test clear and understandable:

yes no

I'll use the course information in my daily practice:

yes no

Overall, I would give this course a grade of _____.

Fax your completed exam to 703-935-2190

Instructions

Read the course material and enter your test answers on the one-page answer sheet included with this book.

You earn course credit for every test answer sheet with at least 70% correct answers. We notify failing students within 7 days and give them an opportunity to take a new test. To claim your credits, return your answers by:

- Taking the test online (only if you have not purchased the coursebook separately, you will need to provide credit card information at the time you submit your exam online for scoring).
- Writing your answers on the one-page answer sheet included with this book, then fax or mail them to:

The Dental Learning Network
1474 North Point Village Center - # 234
Reston, VA 20194
Phone: 800-522-1207
Fax: 703-935-2190

We grade all tests in a timely manner; so if you do not receive your certificate within five days, please send an email to CESupport@DentalLearning.org

There is no time limit for return of your answer sheet. Completion dates are taken from the test answer sheet envelope postmark or the finish date recorded in the computer when you do an online exam, and must be in the licensing cycle you wish to use the credits.

If you are dissatisfied with the course for any reason, please return the printed materials within 30 days of purchase and we will refund your full tuition. Shipping charges are nonrefundable.

If someone else would like to use this material after you are done, he or she may register with us and take advantage of the “sharing discount” workbook tuition charge. Courses downloaded from the Internet can be shared at the same tuition rate as currently available on our website. Please call us if you need an extra answer sheet or download one from our website. There is no “sharing discount” for online exams.

Keep in mind several States have specific requirements on subject matter as well as credits earned through different educational methods for license renewal. You are responsible to know of these limitations. The author and The Dental Learning Network have made every effort to include information in this course that is factual and conforms to accepted standards of care. This course is not to be used as a sole reference for treatment decisions. It is your responsibility to understand your legal obligations and license requirements when treating patients. The Dental Learning Network is not responsible for the misuse of information presented in this course. The material in this course cannot be reproduced or transmitted in any way without the written consent of The Dental Learning Network.

Table of Contents

Instructions	4
Table of Contents	5
Objectives	6
Introduction	7
History of Local Anesthetics	8
Neurophysiology	9
Pharmacology	10
Anesthetic Action	11
Uptake, Distribution, and Elimination	12
Introduction.....	12
Systemic Effects of Local Anesthetics.....	12
Pharmacology of Vasoconstrictors	13
Topical Anesthetics	14
Selection of Anesthetics	15
Toxicity	17
Introduction.....	17
Epinephrine Overdose.....	18
Armamentum	19
Syringes.....	19
Needles.....	20
Cartridge.....	21
Preparation of the Syringe.....	21
Patient Evaluation	22
Injection Techniques	24
General Injection Technique.....	24
Maxillary Anesthesia.....	26
Mandibular Anesthesia.....	28
Other Mandibular Nerve Block Anesthetic Techniques.....	30
Complications	35
Pain on Injection.....	35
Paresthesia.....	35
Hematoma.....	35
Trismus.....	36
Infection.....	36
Double and Blurred Vision.....	37
Facial Nerve Paralysis.....	37
Broken Needles.....	37
Other Methods of Anesthesia	38
Electronic Dental Anesthesia.....	38
Lidocaine Patch.....	38
Test	40

Objectives

Upon completion of this course, the student will be able to:

- Explain the action of a nerve.
- Explain the action of local anesthetic drugs on nerves.
- Describe different techniques of local anesthetic administration, and what teeth are effected by each injection.
- Identify the toxicity level for all anesthetic medications used.
- Identify symptoms of complications that may result from administration of local anesthesia and the treatment for each.
- Understand the rationale behind the use of alternative forms of anesthesia, including sedation and electronic dental anesthesia.

Introduction

Pain control is the foundation of successful dental patient management. Good injection technique is essential for consistent anesthesia. Dental professionals licensed to administer local anesthesia (Dentists and some Dental Hygienists) must use the medications available to them with caution and confidence.

The patient's psychological state must be evaluated before the administration of any anesthesia. A relaxed, confident patient will respond better to local anesthesia. An anxious or phobic dental patient may require some type of intervention strategy to relieve the stress before administering anesthesia. Other considerations such as the health of the tissue (presence or absence of infection) and deviation from normal anatomy must be assessed as well.

This course is a review of currently accepted practices for dental local anesthetic administration. This course will not lead to licensure of local anesthetic administration. The student should be knowledgeable about head and neck anatomy and basic emergency medical procedures for the dental office, including CPR.

History of Local Anesthetics

1500's	Accounts referring to Peruvian Indians chewing on leaves of the coca plant are found.
1884	Carl Koller demonstrated the usefulness of the extract from these leaves (cocaine) as a topical anesthetic for the eyes, and earned distinction as the "Father of Local Anesthesia".
1884	William Halsted used cocaine in the first nerve block (an inferior alveolar nerve block). The use of cocaine for anesthesia produced several unwanted side effects including cardiac problems and addiction.
1885	James Corning demonstrated the use of a tourniquet to slow absorption of cocaine.
1901	Heinrich Braun demonstrated the use of epinephrine to retard local anesthetic absorption from the site of injection.
1904	Alfred Einhorn introduced procaine (proprietary name novocaine) which had far fewer side effects. Epinephrine was needed to constrict the vessels in the area of administration to lengthen the duration of anesthesia. It was common to see a 1:50,000 concentration for many years.
1943	Nils Lofgren introduced lidocaine (proprietary name xylocaine), a synthetic anesthetic with far fewer allergic responses and faster onset of action.
1947	Novocol company made the dental aspirating syringe available.
1959	Disposable sterile needles made available by Cook-Waite, Roehr Company.
(Information from: Malamed, 1994: JADA and Yagiela, 1991: Anesthesia Progress)	

Nerves are groups of cells that act together to be a communication system for the Central Nervous System (CNS). The neuron is the cell responsible for transmitting messages from the periphery of the body to the CNS and from the CNS to the periphery of the body. Afferent or sensory nerves conduct impulses to the CNS while efferent or motor neurons conduct messages from the CNS to the periphery. The sensation of pain is first felt at the skin, tissue, or mucosa and the dendritic zone (made up of free nerve endings) starts the impulse. This impulse follows along an axon to the brain where it is interpreted. After the sensory nerve stimulates the CNS, the CNS decides the best action to take and sends its decision via impulse back through motor neurons to activate muscles. The cell body is involved in this return transmission as well as being responsible for the metabolism of the whole nerve. The axon is a long nerve fiber that runs the whole length of the nerve. It's encased in a nerve membrane called an axolemma. Inside the membrane is a gelatinous substance called the axoplasm. Most axolemmas are surrounded by a myelin sheath.

The most widely held theory on nerve transmission attributes conduction of the nerve impulse to changes in the axolemma, not necessarily the axoplasm or the cell body. In a resting nerve, the electrical resistance keeps sodium, potassium and chloride ions from flowing into the axoplasm. Nerves have a resting potential where the inside or axoplasm has a negative electrical potential. When the nerve is stimulated, the electrical potential is slightly decreased (slow polarization). Then at a certain level of electrical potential called the threshold potential or firing threshold, a rapid depolarization of the membrane occurs. The electrical potential is then reversed resulting in the inside of the nerve being electrically positive and the outside negative. After depolarization, the membrane gradually repolarizes to the normal resting potential. When the nerve is stimulated and an impulse is generated, the conductivity changes and the membrane allows sodium and potassium ions to pass into the axoplasm. This provides the energy for the impulse to continue along the nerve to the CNS.

A local anesthetic prevents the generation and conduction of a nerve's impulse. For a local anesthetic to be clinically useful, it should be compatible with the tissues (not irritating), and its action should be temporary and completely reversible. It should be effective in doses far below its toxic level, it should be hypoallergenic, and have a rapid onset of anesthesia with a duration of action sufficient to complete the dental procedure comfortably.

Local anesthetics are divided into two functional groups based on their chemical properties: amides and esters. The ester group includes the earlier anesthetics procaine, cocaine, and novocaine. The more modern amide group includes lidocaine (or xylocaine), mepivacaine (or carbocaine), prilocaine (or citanest), bupivacaine (or marcaine), and etidocaine (or duranest). The amides are preferable to the esters because the means by which the body breaks down the substance of the drug is less likely to cause an allergic reaction. (Esters are reduced by esterases in the tissue and amides are reduced in the liver and excreted in the kidneys.) The lipid solubility, potency, duration of action, and ionization constant are all preferable in the amide group.

Anesthetic Action

There are several theories concerning the action of anesthetic on nerves. One proven fact is that the anesthetic interferes with how the impulses travel down the length of the nerve itself. This is done by interfering with the influx of sodium ions across the neural membrane. General anesthetics act on the synapses of the central nervous system, while the local anesthetics affect the axonal membranes of peripheral nerves. Local anesthetics act during the depolarization phase of the nerve impulse generation. The rate of depolarization is reduced and the nerve doesn't ever reach the firing potential.

The most popularly held theory postulates that the local anesthetic interferes with the sodium channel and blocks the sodium transfer necessary for nerve conduction (The Specific Receptor Theory). This inhibits sodium flow through the membrane. Different anesthetics bind at different sites in the membrane. The anesthetic must permeate 8 to 10 mm of the nerve's length to profoundly block the generation of the nerve impulse since an impulse can be strong enough to skip over one or two of the nerve cells.

When the procedure lasts longer than the duration of the anesthetic, a second injection may be required to finish the procedure. If the anesthetic molecules once more bond into the appropriate sites on the nerve membrane, profound anesthesia is usually rapid. If the anesthetic does not produce pain control on the second injection, it may be because of a lower pH of the tissues, edema, hemorrhage, or transudation in the surrounding area. If the patient indicates pain, the nerve has returned to function and it is usually more difficult to achieve profound anesthesia again. Anesthetics are not as effective when infection is present because the pH of the tissues is too low to allow the anesthetic to penetrate the nerve sufficiently.

Nerve fibers are categorized based on diameter. The three types are A fibers (largest), B fibers and C fibers (smallest). Type C fibers are unmyelinated and responsible for carrying the sensations of pain and temperature. They are most easily blocked by local anesthetic. The lack of a myelin sheath allows easier access to the nerve. Type A fibers are the largest and are responsible for carrying pressure and motor sensation. Local anesthetics are not as effective at blocking these fibers. This is why an adequately anesthetized patient can always feel pressure during an extraction, but not pain.

Uptake, Distribution, and Elimination

Introduction

The blood flow in the area of administration, affinity of the anesthetic for local tissues, effect of anesthetic on circulation, and the absence or presence of a vasoconstrictor all influence the uptake of local anesthetics. Highly vascular organs like the brain, liver, lungs, and kidneys will have higher blood levels of anesthetic following injection than other less vascular areas.

When an amide anesthetic is absorbed by the bloodstream, it is bound to the plasma proteins and red blood cells. It is distributed to all tissues in the body. When administered in normal doses, the anesthetic is distributed so that no single tissue reaches a toxic level. Intravascular injection results in a sequential distribution first to the lungs then rapidly distributed to other organs with large blood supplies, especially the brain, heart, liver, kidneys, spleen and then to muscle and fat.

Systemic Effects of Local Anesthetics

Local anesthetics block action potentials in the tissues it comes in contact with. The Central Nervous System and the cardiovascular system are susceptible to effects of local anesthetics. At toxic blood levels, anesthetics can depress the CNS and cause the patient to have convulsions. Patients who are epileptic are more susceptible to seizure. The seizure may be prolonged and the patient's respiratory and circulatory activity must be monitored after the episode.

The circulatory system is more resistant to the effects of local anesthetics. A typical dental dose is not enough to cause myocardial depression that would lead to circulatory collapse.

The ester anesthetics are metabolized in the bloodstream by pseudocholinesterase. Approximately one in 2800 people will have atypical pseudocholinesterase and cannot biotransform the anesthetic at a normal rate. Ester anesthetics are contraindicated in patients who report atypical pseudocholinesterase production.

The amide anesthetics are metabolized in the liver. Patients who have liver dysfunction may have difficulty in metabolizing these drugs and will reach a toxic level more quickly than a healthy counterpart. The kidneys then excrete the small amount of anesthetic that was not metabolized in the liver as well as the metabolites from the liver into the urinary system.

Pharmacology of Vasoconstrictors

The vasodilation activity of local anesthetics produce an increased rate of absorption. This results in decreased effectiveness, short duration of anesthesia, and a higher risk of toxicity. Bleeding in the area of injection is increased. Vasoconstrictors are clinically useful in counteracting these effects. Vasoconstrictors are added to local anesthetics to decrease the absorption of the drug and prolong the anesthetic effect that produces anesthesia that is more profound. The vasoconstrictor also serves to reduce the risk of toxicity because it is more slowly absorbed by the circulatory system. The length of the procedure, desired level of hemostasis, and the medical health of the patient must all be considered when selecting an appropriate vasoconstrictor.

Epinephrine and levonordefrin (neo-cobefrin) are the most commonly used vasoconstrictors in dentistry. Epinephrine is sensitive to heat and can be inactivated if left too warm for too long. Store local in cool areas and never autoclave the cartridges. If a warmer is used, rotate new cartridges in regularly and don't leave the warmer on over night.

Neo-cobefrin is not as potent as epinephrine. A common dilution of neo-cobefrin is 1:20,000 which delivers basically the same amount overall as epinephrine. (Five times the amount of neo-cobefrin is needed to produce the same results as epinephrine.)

Epinephrine is available in concentrations of 1:50,000 for better hemostasis. Many studies have shown that clinically, there is not much difference in the hemostasis of 1:200,000 over 1:50,000. The anesthetic effect lasts much longer with the 1:50,000 concentration. Vasoconstrictors are effective in producing hemostasis, but after they wear off, it may lead to increased postoperative bleeding (rebound effect). This is especially true in higher concentrations.

The use of vasoconstrictors should be carefully weighed against the risks for patients that are medically compromised by high blood pressure, cardiovascular disease, or hyperthyroidism. If the patient's condition is controlled with medication, slow administration with sure negative aspiration may be acceptable. No more than 2 cartridges of lidocaine with 1:100,000 epinephrine should be used on epinephrine sensitive patients.

Epinephrine is contraindicated in patients with:(from Malamed *Handbook of Local Anesthesia*)

- blood pressure over 200 torr systolic or 115 torr diastolic,
- uncontrolled hyperthyroidism,
- severe cardiovascular disease including less than 6 months after a myocardial infarction or cerebrovascular accident
- daily episodes of angina pectoris or unstable angina
- cardiac dysrhythmias despite appropriate therapy
- medicated with β -blocker, monoamine oxidase inhibitors, or tricyclic antidepressants; or general anesthesia with a halogenated anesthetic like halothane, methoxyflurane, or ethrane.

Patients with the above conditions should be referred to their physician for treatment and dental treatment should be delayed until the physician indicates that it is safe.

Topical Anesthetics

Topical anesthetics are used prior to the administration of local anesthetics and for some procedures like scaling or removal of a very loose primary tooth. The concentration of topical anesthetics is higher and the absorption is greater, so toxic levels are more easily reached. The anesthesia is effective only about 2-3 mm of depth into the tissues on which it is applied.

Topical anesthetic is available in gel or spray form. The gel type of topical is recommended because it can be dispensed in premeasured doses. It is too difficult to measure the dose of the spray type, the patient may aspirate the spray, and the can is difficult to sterilize. Benzocaine is a commonly used topical anesthetic. It is an ester, so localized allergic reactions may be noted. Benzocaine is chemically ethyl-aminobenzoate, $C_9H_{11}NO_2$, with a molecular weight of 165.19.

Lidocaine is available in topical form, but the maximum recommended dose in this form is 200 mg.



Selection of Anesthetics

The duration of action, the maximum suggested dosage, and the contraindications regarding particular local anesthetics must be considered prior to their use.

Duration of a drug can only be approximated because several factors influence the action of the local anesthetic. Some of these factors are:

- anatomical variation,
- type and method of injection,
- presence or absence of infection (pH of the tissues),
- the patient's individual response to the anesthetic,
- anxiety,
- vascularity of tissues.

The approximate duration for several common anesthetics are as follows: (from Malamed Handbook of Local Anesthesia)

Agent	Approx. Duration of Anesthesia*
<i>Bupivacaine hydrochloride</i>	
0.5% with epinephrine 1:200,000	>90 min.
<i>Etidocaine hydrochloride</i>	
1.5% with epinephrine 1:200,000	>90 min.
<i>Lidocaine hydrochloride</i>	
2% without vasoconstrictor	30 min.
2% with epinephrine 1:50,000	60 min.
2% with epinephrine 1:100,000	60 min.
<i>Mepivacaine hydrochloride</i>	
3% without vasoconstrictor	30 to 60 min.
2% with levonordefrin 1:20,000	60 min.
<i>Prilocaine hydrochloride</i>	
4% without vasoconstrictor	30 min.
4% with epinephrine 1:200,000	90 min.
*for pulpal anesthesia, soft tissue longer	

The variety of available anesthetics makes it easier for the practitioner to tailor the anesthetic to the specific needs of the patient. Each time anesthetic is employed, consider the time needed for the procedure, the potential for postoperative pain, the possibility of injury with long duration postoperative anesthesia, and the physical and emotional status of the patient.

Lidocaine is the most commonly chosen anesthetic today. The most popular contains epinephrine 1:100,000 and provides good anesthesia for healthy patients. Lidocaine with epinephrine 1:50,000 is used for hemostasis, but because of the rebound effect noted earlier, it should be used sparingly. 3% Mepivacaine without a vasoconstrictor is used as anesthetic for patients who cannot take a vasoconstrictor or for short procedures. It is appropriate for pedodontics and for use on geriatric patients. 2% Mepivacaine with vasoconstrictor provides pulpal anesthesia that is similar to lidocaine with epinephrine, but hemostasis is not as intense. The action of prilocaine plain varies with the area injected (longer with a nerve block), but usually provides anesthesia similar to lidocaine and mepivacaine with vasoconstrictor. Prilocaine with vasoconstrictor gives good anesthetic effect and uses a 1:200,000 concentration of epinephrine. Bupivacaine is used when pulpal anesthesia is desired for longer appointments and when postoperative pain is anticipated. Some practitioners may prescribe nonsteroidal anti-inflammatory agents prior to the appointment, use an intermediate duration anesthetic for the procedure, inject bupivacaine just prior to the patient's dismissal, and direct the patient to take oral analgesics for a certain number of days following the procedure. Bupivacaine is not recommended for children or handicapped patients because of the increased risk of postoperative injury (chewing on a numb lip).

Articaine is a newer anesthetic typically given in a 4% solution with 1:100,000 epinephrine. It is widely used in Europe and has recently gained popularity in the U.S. Articaine reportedly is more potent than Lidocaine and, therefore, requires less to achieve a similar state of anesthesia. Practitioners reported rarely missing an inferior alveolar nerve block with Articaine. However, concern has arisen about its potential for tissue necrosis and persistent nerve paresthesia.

Introduction

Local anesthetics are linked to 50% of the deaths in the dental office. Use the smallest dose that will produce adequate anesthesia. Toxicity can be reached for any anesthetic by administering too much of the drug (especially as related to the patient's body weight), administering the drug to a sensitive individual, administering the drug into a blood vessel, or by improper drug combinations. Local anesthetic drugs affect the cardiovascular system, the nervous system, and local tissues. If the level of the drug is too high, it can become toxic causing a dangerous reaction in the nervous system, cardiovascular system, or in the local tissues. The rate of absorption and elimination of the drug is directly related to its toxic effects. The faster it is absorbed by the bloodstream and the slower the metabolism of the drug, the more toxic it is to the body.

Toxicity Equations

mg per cc. \times 1.8 = mg per cartridge

patient weight \times toxic limit for the drug = toxic limit in mg

toxic limit in mg \div # mg in cartridge = maximum cartridges allowed

Administer Less Than Maximum Cartridges Allowed or Less Than Maximum Dosage Allowed, Whichever Is Less.

Always take the weight of the patient into account.

Injection of even a small amount of anesthetic solution directly into a blood vessel can result in an immediate toxic level. It is critical to aspirate each time an anesthetic is administered into an area that is very vascular, but negative aspiration does not guarantee that the bevel of the needle is not in the vessel. However, if the practitioner aspirates multiple times during the slow injection of anesthetic, chances of injection into a vessel are reduced.

Toxic limits are for normal, healthy patients. Some patients will be more sensitive to drugs so they may react to an even smaller dose than someone else regardless of their weight. If the patient is overly sleepy or lethargic after administration of the local anesthetic, it may be a symptom of toxicity.

Any time the patient is taking another CNS depressant, the mixture of the drugs will reduce the toxic level for the anesthetic. Patients should be questioned as tactfully as possible prior to anesthetic administration if there have been any drugs (prescription, over the counter, or street contraband) ingested recently. If the dentist prescribes preoperative anxiety relieving drugs such as Valium or Demerol, the dose of local anesthetic should be monitored even more carefully.

Signs and symptoms of local anesthetic toxicity include: slurred speech, excitement, shivering, muscular twitching, and tremor of facial muscles and extremities. The patient may also feel numbness of the tongue (on the opposite side of a mandibular block or in maxillary anesthesia), warm, flushed skin, lightheadedness, dizziness, diminished sight, tinnitus, and disorientation. These signs and symptoms may not be present when using lidocaine and prilocaine. Toxic levels of these anesthetics usually produce mild sedation or drowsiness. If the patient indicates

an excitement reaction, observation is usually all that is necessary. Do not dismiss a patient or leave the patient alone if they are exhibiting any reaction symptom. As the concentration of anesthetic in the bloodstream increases, the patient may go into a seizure. As with all seizures, the most important first aid measure is to place the patient in a position where they will not be hurt and move all dental instruments away from the area. Do not put anything in the patient's mouth. If the seizure continues and the patient has lost the ability to breathe, artificial respiration must be administered. If the seizure does not become self-limiting, it may be necessary to administer 5 mg of Valium. Watch the patient's vital signs, they may go into respiratory arrest. Usually if the patient is properly ventilated, the effect of the anesthetic will wear off and the patient should be able to breathe on his or her own after about 15 minutes.

The table below lists maximum recommended doses and toxic limits for the most common anesthetics (from Malamed *Handbook of Local Anesthetics*)

Drug	Toxic Limit	Maximum
2% Lidocaine (Xylocaine)	2 mg/lb	300 mg
3% Carbocaine(Mepivacaine)	2 mg/lb	300 mg
4% Citanest (Prilocaine)	2.7 mg/lb	400 mg
1.5% Duranest (Etidocaine)	3.6 mg/lb	400 mg
0.5% Marcaine (Bupivacaine)	0.6 mg/lb	90 mg

Before administering any anesthetic, calibrate the dose of anesthetic in the cartridge. The percent of the solution is the indicator of concentration. For example, 2% lidocaine is 20 mg of xylocaine per cc of the drug. Multiply this number by 1.8 (because of the cartridge containing 1.8 cc. of solution). 2% xylocaine is 20 mg per cc x 1.8cc = 36 mg per cartridge. So for a 180 lb patient the maximum dose is 2 mg/lb x 180 divided by 36 mg in the cartridge = 10 cartridges. But the maximum dose for this drug is 300 mg which is **8 cartridges**. In the same patient, the maximum dose for citanest would be 5.5 cartridges.

Children have a smaller body weight, so the toxic level will be reached faster. Remember to take the patient's weight into account when figuring the maximum dose of any local anesthetic. For a 50 lb. child, using 2% lidocaine: **2 mg/lb x 50 divided by 36 mg in the cartridge = 2.7 cartridges**.

Epinephrine Overdose

Symptoms of epinephrine overdose include: fear, anxiety, restlessness, headache, tenseness, perspiration, dizziness, tremor of limbs, palpitation, and weakness. The patient's blood pressure and heart rate will be elevated. Patients with weakened hearts are especially at risk because their cardiovascular system is already compromised.

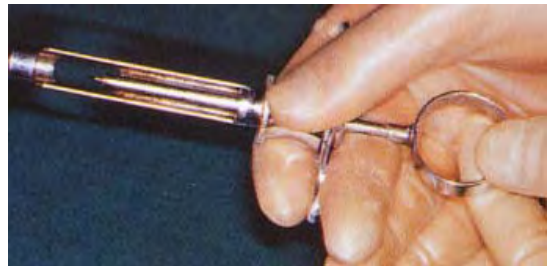Position the patient comfortably and administer oxygen. If the patient's blood pressure is elevated and signs of a cerebrovascular incident occur, summon medical assistance. The patient should gradually recover. If there are no symptoms of cerebrovascular problems, the patient can be dismissed home. Otherwise they should go to their physician or the emergency room depending on the seriousness of the episode.

Syringes

Five types of syringes are available for dental use:

- breech - loading,
- metal (aspirating, self aspirating, or nonaspirating);
- pressure injectors;
- jet injectors;
- and plastic (autoclavable or disposable).

The metal aspirating type is the most commonly seen in practice today. The aspirating type has a harpoon to plunge the rubber stopper of the cartridge of anesthetic. When the thumb ring is pulled back slightly, the negative pressure produced will aspirate blood into the cartridge if the needle is in a vessel (positive aspiration). The effect of direct



injection of local

anesthetic into a vessel is so severe that every time local is being injected into a vascular area, multiple aspirations of this type should be performed. Self-aspirating syringes make aspiration easier for those with smaller hands. Correct technique is essential for optimum performance. Non-aspirating syringes should not be used or available in the office where they may be accidentally used. The


metal type of syringe is autoclavable.

Pressure syringes for intraligamentary injection or periodontal ligament injections are popular. The mechanics of the syringe makes administration of these higher pressure injections much easier. Pressure syringes also make it easier to administer the solution too quickly, resulting in damaged or bruised tissues. Patients may complain of postoperative soreness in the area of the injection. The injection should be administered slowly with this type of syringe (20 seconds for the .2 ml delivered in one dose) to reduce the amount of damage to the tissues.



Syrijet Mark II

Needleless injectors like the Syrijet and Madajet use pressure to deliver local anesthesia to soft tissues 2 to 3 mm in depth. The effect is similar to topical anesthesia. Further injections are required for profound soft and hard tissue anesthesia. Improper use can result in tissue damage and postoperative discomfort.



Madajet XL

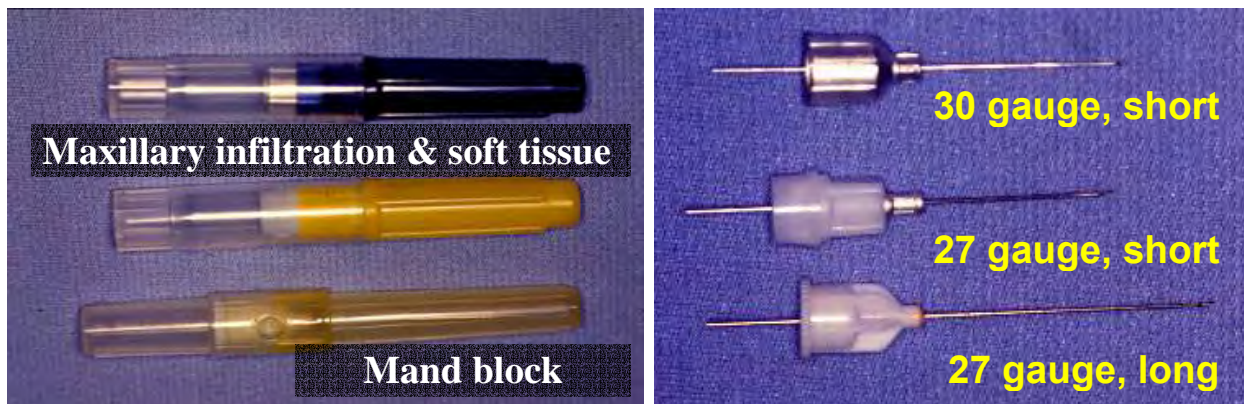
Plastic syringes are lighter and may be more esthetically pleasing to anxious patients.

Needles

Careful consideration should be given when choosing the length and gauge of the needle used for each injection. A needle should never be inserted to its hub because it is the most likely place for a needle to break. Retrieval of a broken needle embedded into tissue usually requires surgery but a needle can be pulled out with a hemostat if some of it is protruding from the tissue. Long, 25 gauge needles should be used for the inferior alveolar nerve block, the Gow-Gates mandibular nerve block, and the Akinosi mandibular nerve block. Short 25 or 27 gauge needles are used with other injections. Many practitioners use a 30 gauge needle thinking that the patient will not feel the penetration as much. If topical gel is adequately applied to the tissue, the patient will not feel the difference in gauge and studies show a more accurate aspiration with larger gauge needles. Smaller needles tend to bend and deflect as they are inserted into tissue, so the accuracy of the injection can be compromised.

A needle that is inserted more than 3 or 4 times on the same patient should be changed if more injections are needed because it will usually become dull and the patient will feel the insertion. If the needle contacts bone and will be used again, check for barbs that can cause discomfort during withdrawal of the needle. A needle that has a barb will snag a gauze square as it is drawn across the tip.


Common dental needles



Use a new, sterile disposable needle and fresh cartridge of anesthetic for every patient requiring local anesthesia. Never reuse needles or cartridges on different patients. Handle needles very carefully because they easily puncture gloves and injure skin. Recap needles using a safe method or set them in a safe place without recapping them. If recapping, do not hold the cap with your hand, use a recapping device or "scoop up" the cap without touching it. Use forceps to steady the cap. Never leave an uncapped needle on the treatment tray, because it is more likely to cause injury. Place it in a "sterile field" away from the bracket table until the procedure is complete. Treat an unsheathed needle as if it were a loaded gun. Many health care worker injuries occur when they attempt to either recap or bend the needles before disposal. The used sharps must be contained in puncture-resistant containers, so there is no need to either recap or bend the needles for disposal. Use hemostats or pliers to remove the needle from the syringe and place directly into the container.

Cartridge

Cartridges used in the United States contain 1.8 ml of anesthetic in solution. It is commonly called a "carpule" - the registered trade name used by Cook-Waite Laboratories.



The stopper is treated with silicone to make it slide more smoothly during injection. On the opposite end of the cartridge is an aluminum cap and a semi-permeable rubber membrane where the needle is inserted. The aluminum is especially sensitive to corrosion by some disinfectant and sterilant solutions. The semipermeable membrane can allow passage of fluids if the cartridge is submerged in liquid.

The solution in the cartridge contains the local anesthetic, sodium chloride, distilled water, and if indicated, a vasoconstrictor drug with preservative. Methylparaben was added to the cartridge before 1984 as a preservative, but it has since been removed because it was the most likely substance to cause an allergic reaction in the patients.

Sodium bisulfite or metabisulfite in the solution may be a problem for some sensitive individuals. It has antioxidant properties used in anesthetic cartridges containing a vasoconstrictor. Cases have been reported to the FDA about asthmatic patients having an allergic reaction to the bisulfites used on food (such as a salad bar, used to maintain freshness). No cases have been reported in the dental office, but asthmatics that have had reaction to bisulfites should not be administered local containing a vasoconstrictor. When a patient indicates asthma as a condition on the medical history, additional questioning is prudent to avoid a reaction to the antioxidant.

Some practitioners submerge the cartridge in alcohol. The rubber diaphragm can be wiped with alcohol prior to insertion of the needle, but the alcohol may diffuse into the solution through the diaphragm if it is left to soak.

Some manufacturers add a small bubble of nitrogen gas to the cartridge to keep oxygen out. If there is a larger bubble and the rubber stopper is extruding from the end of the carpule, it may have been damaged or frozen. Return the whole can to the manufacturer.

Preparation of the Syringe



The syringe should be removed from its sterile wrap after autoclaving. The cartridge is inserted into the syringe. The harpoon is engaged with gentle, steady finger pressure with the plunger until the rubber stopper is embedded. Some practitioners embed the harpoon by slamming the ring with their palm.

This can lead to fractures of the cartridge glass and the cartridge may break and cause injury to the patient or practitioner. After the harpoon is engaged, the needle is then attached to the hub and a few drops of anesthetic expelled to test the flow. A self-aspirating syringe should be loaded with the cartridge and then the needle attached to the hub.

Patient Evaluation

A thorough medical history is an indispensable part of any patient's record, whether they look healthy or not. It is essential from the medicolegal standpoint as well that all medical conditions be charted and noted with the date of entry. An excellent medical history form is available from the American Dental Association (long form). Dental schools also usually have thorough up-to-date forms.

Orally review any positive answers and provide an explanation in the chart. Note the date of their last physical examination. If the patient doesn't go to the doctor because they've always had good health, be suspicious that there may be an undiagnosed underlying medical problem and recommend a complete physical evaluation. Update the medical history at every appointment with a clear notation in the chart as to the status of the medical history ("10/22/94 Medical History reviewed, no changes"). Make sure the form is signed and dated by the patient and the reviewing dentist. Complete the entire form in ink.

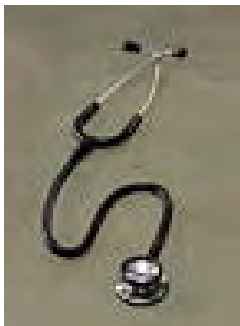It is important to evaluate the patient's health before beginning any treatment because certain factors may change the method of treatment. The dentist must evaluate the patient's ability to tolerate (both physically and psychologically) the stress of treatment.

A decision must be made before any anesthetic is administered to either:

- administer medication to the patient and proceed with treatment,
- postpone treatment until the personal physician is consulted, or
- reschedule the patient for another day.

If the hygienist has any doubts, they should consult the supervising dentist.

The patient's vital signs: blood pressure, heart rate, and respiration rate should be taken and recorded in the patient's chart before the injection of local anesthetic. To obtain a pulse rate, palpate the radial or brachial artery with your first two fingers (never the thumb because your own pulse is felt there) and count the beats for 1 minute. Characterize the beats as strong and steady, bounding, thready, or weak. "Strong and steady" indicates a normal, healthy pulse, any other description may indicate a problem. Normal respiration is 16 to 18 breaths per minute. Count the breaths per minute without calling attention to it so the patient will not consciously change the rate.



A baseline blood pressure reading should be taken on all patients at the initial exam. Seat the patient in the dental chair with their arm at heart level, elbow slightly flexed, and resting on the armrest or another supportive surface. Let the patient relax for a few minutes before taking the blood pressure. Wrap the cuff around the arm closest to you with the center of the inflatable portion over the brachial artery. The rubber tubing should lie medially to the arm. The bottom edge should be one inch above the bend of the elbow. The cuff should be tight enough that it will not slip off the arm, and loose enough that two fingers can fit under it when it is deflated. Find the radial pulse at the medial aspect of the wrist. Inflate the cuff about 30 torr above the point where the pulse disappears. Place a stethoscope at

the antecubital fossa (inside the bend of the elbow) where it doesn't touch the tubes or cuff. Gradually deflate the cuff and note the number on the gauge when the first sound is heard. This is the systolic pressure. Continue gradually deflating the cuff until there is no sound. This point is the diastolic pressure. Note on the patient's chart the pressure as a fraction: systolic/diastolic and right of left arm. (120/85 R)

Common errors in taking blood pressure include:

Cuff too loose	Can result in a reading that is too high
Wrong cuff size	Use a cuff that is about 20% greater than the diameter of the arm. Have a pediatric cuff for children, a regular adult cuff, and a large cuff for heavy patients
Not palpating the pulse and underinflating the cuff	Blood pressure may be high, but because the cuff wasn't inflated above the pulse cessation point the reading may be falsely low
Using visual cues rather than audio indicators	Though the gauge may "twitch" rely only on the sounds appearing and disappearing

The American Society of Anesthesiologists' Physical Status Classification System is a good reference for blood pressure relative to safety for treatment. If the patient's blood pressure is less than 140/90, it is safe to deliver routine dental treatment. Check the pressure in six months. If the patient's pressure ranges from 140 to 159 over 90 to 94, routine dental treatment can be delivered. Recheck the pressure before the next three appointments and if it is still in this range refer the patient to their physician for evaluation. If the patient's pressure ranges from 160 to 200 over 95 to 114 retake it after waiting 5 minutes. If still in this range, refer the patient to their physician for evaluation and consider stress reduction instruction. Routine dental care can be delivered, but a consultation with their physician is recommended before administration of anesthesia. If the patient's pressure is over 200/115, recheck it after 5 minutes and if still elevated, consult with their physician. If emergency dental treatment is necessary, it may need to be performed in the hospital.

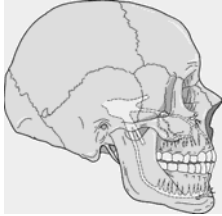


A patient with liver or kidney dysfunction may have a problem metabolizing amide anesthetics. Consult with the patient's physician before administering if there is any doubt.

Any patient who reports an allergy to local anesthetics should be questioned thoroughly. True allergic reactions are rare but possible. The only way to accurately diagnose a true allergy to anesthetics is to order a potency test from the patient's physician. Some patients who believe they are allergic actually had a hematoma, trismus, or felt anxious because of the vasoconstrictor. If a patient is found to be truly allergic to all local anesthetics, all dental work involving pain should be conducted in the hospital under general anesthesia.

Injection Techniques

General Injection Technique



The more relaxed, competent, and compassionate practitioner delivers the most painless injections. (A relaxed patient receives anesthetic much better as well.)

The area where the local anesthetic is deposited, relative to the nerve of the tooth to be anesthetized, is the determining factor of the extent of anesthetic effect. Local infiltration techniques deposit the solution near superficial nerve endings and the pain reduction is relatively limited to that area. This technique is used to treat isolated areas, and an example is papillary infiltration for root planing a pocket. Field block anesthesia techniques deposit the solution near terminal branches of nerves to provide anesthesia for a wider area of treatment. This would provide anesthesia for two or three teeth and an example would be injection near the apex of a tooth that anesthetizes the tooth as well as the surrounding tissue. Nerve block techniques deposit the anesthetic close to the main nerve trunk and allow for a wider area of treatment with profound anesthesia. An example is the mandibular nerve block that anesthetizes the teeth, tissue, and tongue of the patient on the side of administration. The following techniques are similar to and verified by the text of "Handbook of Local Anesthesia" third edition by Stanley Malamed. The handbook is excellent in its explanation and diagrams and is highly recommended. The figures to follow show only the general area for the injection and are not meant to be anatomically precise.

The most successful atraumatic technique was developed by Dr. Friedman at USC, and outlined in detail in Dr. Malamed's *Handbook of Local Anesthesia*. The general guidelines include:

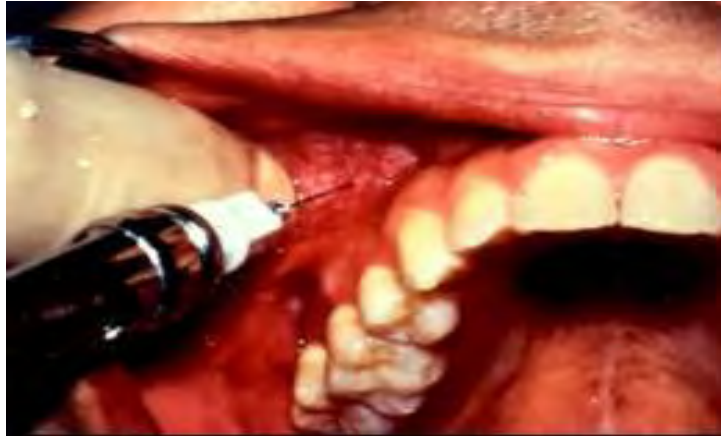- Use a sterile, sharp needle. Use an appropriate gauge and length of needle for the injection site. Check the flow of anesthetic by expelling a few drops of local from the cartridge.
- Armamentum and anesthetic should be room temperature.
- The patient should be reclined comfortably to reduce the incidence of fainting (head parallel with the heart and feet raised slightly).
- Use gauze to dry the area of injection. Communicate with the patient at this time that you are taking steps to make sure the procedure will be as comfortable as possible.
- Apply a topical antiseptic with a cotton tipped applicator to reduce the incidence of infection. Use Betadine or Merthiolate, not one containing alcohol because it can irritate the tissues.
- Apply topical anesthetic to the area of tissue penetration with a cotton tipped applicator. Keep the applicator in place for two minutes to allow the topical time to take effect. Explain to the patient at this time about the topical gel, how it anesthetizes the area and makes the procedure more comfortable. Use positive terms like anesthetic, comfortable, and procedure rather than novocaine, pain, or shot. Try not to make promises that are unreasonable like "You won't feel anything" or "This won't hurt".
- Have the armamentum behind the patient and passed out of the field of vision.
- Pull the tissue as taut as possible.
- Use a firm handrest and move with purpose.

- The patient picks up on an operator's unsteady delivery or unsure movements and mistakes it for ineptness. Be gentle but in firm control.
- Penetrate the tissue up to the end of the bevel. Watch the patient for any signs of discomfort and slowly deposit a drop or two of anesthetic.
- Advance the needle slowly to the target depth and deposit a few drops of anesthetic as you go. If you approach bone, make sure to deposit a few drops of anesthetic and wait a few seconds because this area is highly innervated.
- Aspirate: Draw the plunger ring back just a few millimeters to produce negative pressure within the cartridge. If blood is visible in the cartridge, withdraw the needle slightly and aspirate again. If there is no visible blood, deposit a few drops of anesthetic and aspirate again. If still negative, slowly deposit more anesthetic.
- Slow depositing of the anesthetic keeps the tissues in the area from tearing and reduces postoperative discomfort. Deposit about 1/4 of the required dose, then aspirate again. Continue aspirating and depositing until the desired dose is administered.
- Slowly withdraw the needle.
- Be careful recapping the needle and use a proper technique.
- Make sure someone stays in the room with the patient to observe any adverse reaction to the anesthetic. Enter the type of anesthetic used, what concentration of vasoconstrictor, how much solution was administered, what gauge needle used, what type of injection method used (PSA, ASA, etc.), and the patient's reaction in the patient's chart.

Maxillary Anesthesia

Supraperiosteal Injection

The supraperiosteal injection is the most popular injection technique for the pulpal anesthesia of maxillary anterior teeth. Sometimes this injection technique is referred to as infiltration, but the solution is deposited near terminal branches of nerves so it is actually a type of field block. This injection is ideal for pulpal and soft tissue anesthesia. If infection is present near the apex of the tooth of choice or if the bone is very dense, this technique may not provide adequate anesthetic effect. If the whole quadrant is involved, this technique would require many needle insertions and postoperative discomfort might result. A short 25 or 27 gauge needle is recommended for this technique. It is inserted at the height of the mucobuccal fold near



the apex of the tooth to be treated. The bevel of the needle should be toward the bone. Slowly deposit approximately 1/3 of the cartridge of anesthetic near the apex of the tooth after negative aspiration has been confirmed. The area should be anesthetized within 5 minutes of injection.

Posterior Superior Alveolar Nerve Block

The posterior superior alveolar (PSA) nerve block is a commonly used technique for achieving anesthesia for the maxillary molars. The short 25 or 27 gauge needle is recommended to decrease the risk of a hematoma. The needle is inserted at the mucobuccal fold by the maxillary second molar with the bevel toward the bone. The needle's route is up, back, and inward towards the PSA nerve. In a normal sized adult, the needle should be inserted approximately 16 mm. The depth will vary according to the bony structures of the patient. Aspirate twice, while depositing a few drops of local in this area. Deposit approximately 1/4 of the cartridge of anesthetic and aspirate again. Repeat this process of aspiration and injection until 3/4 to a full cartridge of anesthetic has been deposited with no positive aspiration. The PSA nerve in some patients does not innervate the mesiobuccal root of the first molar, so more anesthetic may be needed for the Middle Superior Alveolar Nerve.

Middle Superior Alveolar Nerve Block

Only about 20% of patients will have a middle superior alveolar (MSA) nerve. If the infraorbital nerve block does not provide adequate anesthesia to the teeth distal of the canine or if the PSA injection does not provide anesthesia for the mesiobuccal root of the first molar, an MSA block injection should be administered. A 25 gauge short needle is recommended with insertion in the mucobuccal fold by the maxillary second premolar. The bevel of the needle is towards the bone. About 1/2 to 2/3 of a cartridge of anesthetic is slowly deposited at the height of the apex of the second premolar after negative aspiration.

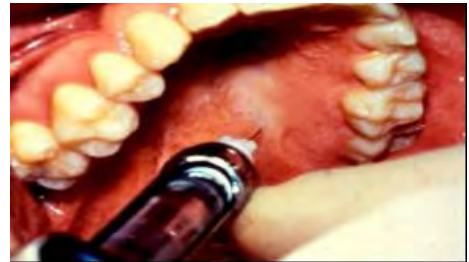Infraorbital Nerve Block

An infraorbital nerve block will provide anesthesia from the maxillary central incisor to the premolar area in about 70% of patients. It is preferred to multiple supraperiosteal injections because it uses less anesthetic and only one penetration of the needle will be necessary. This injection technique will anesthetize the anterior superior alveolar nerve, the middle superior

alveolar nerve, the inferior palpebral nerve, the lateral nasal nerve, and the superior labial nerve. It is especially effective if there is infection of one or more of the teeth because anesthetic will be deposited away from the infection. Locate the infraorbital foramen near the lower border of the orbit. A 25 gauge long needle is recommended and inserted with the bevel toward the bone in the mucobuccal fold over the first premolar. When the needle is inserted the syringe should be parallel with the long axis of the tooth. The needle depth will be about 16 mm for an average sized adult with varying depths proportional to the size of the patient and the bony structure of the cheek. Deposit 1/2 to 2/3 cartridge of anesthetic after negative aspiration is confirmed. After the needle is withdrawn, apply finger pressure to the exterior of the face over the foramen area for a few minutes to help the anesthetic into the foramen.

Palatal Anesthetic Techniques

Strict adherence to proper technique will result in the most pleasant palatal injection possible. Dry the palatal tissue. Swab the area with an antiseptic solution. Apply topical anesthetic for 2 minutes with a cotton tipped applicator. Apply enough pressure with the cotton tipped applicator to the area of injection to cause visible blanching of the tissues. Use a secure hand rest. Deposit the solution slowly so it diffuses through the tissue rather than tearing or bruising. Confident, careful administration of local anesthetic into the palate can be atraumatic, regardless of the density of the tissue and the bad reputation earned by rough pumping of anesthetic by some practitioners.



Greater Palatine Nerve Block

The greater palatine nerve innervates the palatal tissues and bone distal of the canine on the side anesthetized. Use a 27 gauge short needle with the bevel toward the palate. Palpate the palate until the depression of the foramen is felt (usually somewhere medial to the second molar). Dry the tissue, and apply antiseptic and topical anesthetic for 2 minutes. Apply pressure with the swab for 30 seconds. Continue pressure with the swab until the injection is completed. Place the bevel against the tissue and apply pressure enough to slightly bow the needle. Inject a few drops of anesthetic. Release the pressure of the needle and advance the tip of the needle into the tissue slightly. Continue with this procedure of applying pressure to the bevel and depositing a few drops of anesthetic, then advancing, until the needle is in contact with the palatal bone. Deposit less than a fourth to a third of a cartridge of anesthetic after negative aspiration is proven.

Nasopalatine Nerve Block

The nasopalatine nerve innervates the anterior of the hard palate from the mesial of the first premolar bilaterally. The technique is the same as for the greater palatine nerve block, but the site of injection is just posterior to the incisive papillae. The pressure on the cotton tipped applicator is delivered on the incisive papillae. The anterior area may be anesthetized first to diminish the discomfort of the palatal injection. Infiltrate in the mucobuccal fold near the frenum, then infiltrate the papillae between the incisors, then perform the nasopalatine injection. The main drawback of this technique is that it takes more local anesthetic, but the labial injections are often needed anyway.

Different areas of the palate can be anesthetized by local infiltration into the papillae as well, especially if the procedure involves only one or two teeth.

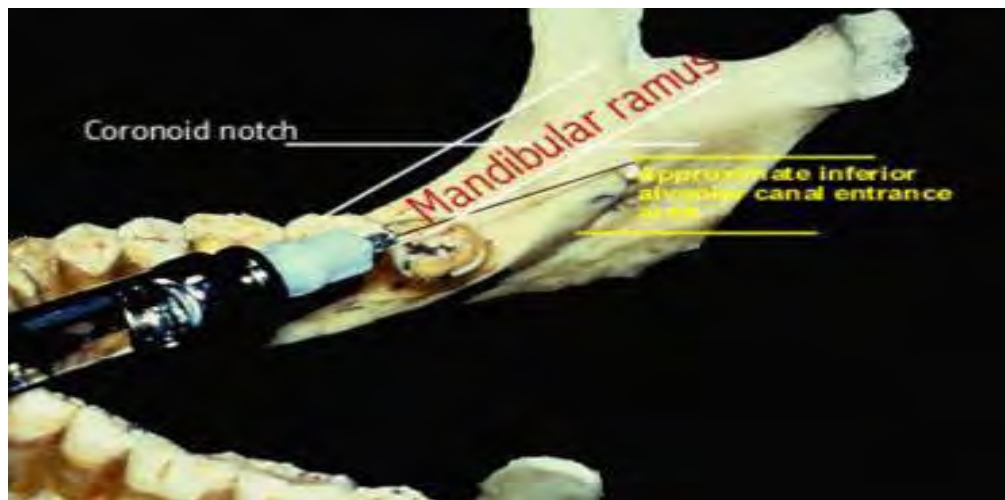
Maxillary Nerve Block

The maxillary (V₂) nerve innervates half of the maxilla, including the buccal and palatal aspects. This injection technique is used especially in quadrant surgery or when extensive treatment is indicated for a single appointment. It is also used when another site of injection has failed or if there is an infection in the area. This technique is used more with adult patients. This technique is not for the inexperienced, and if any doubt exists, the practitioner should take a hands-on course at their local dental school. Administration through the buccal aspect involves the possibility for hematoma. The long 25 gauge needle is recommended with the bevel of the needle facing the bone. The needle is inserted at the mucobuccal fold near the distal of the second molar after the usual protocol of tissue preparation. The path of the needle is similar to that of the PSA nerve block, but is inserted approximately 30 mm to the pterygopalatine fossa. Aspirate, then rotate the needle bevel 1/4 turn, reaspirate. If both aspirations are negative, slowly deposit one cartridge of anesthetic (deposit 1/4 then aspirate, then deposit 1/4 until the entire cartridge has been administered).

This nerve may also be accessed through the greater palatine foramen on the palate. A 25 gauge long needle is recommended, and the same technique is used as for the greater palatine injection. The needle is guided into the foramen to 30 mm. If resistance is felt, it could be due to bony obstruction, and the needle should not be forced. Aspirate, then rotate the needle 1/4 turn and reaspirate. If both aspirations are negative, slowly deposit a cartridge of anesthetic with occasional aspirations.

Mandibular Anesthesia

The success rates for mandibular anesthesia are significantly lower than with maxillary anesthesia. The bone is more dense around the mandibular apices, which inhibits the diffusion of the anesthetic. The anatomical variations from patient to patient can make a textbook-perfect injection ineffective.

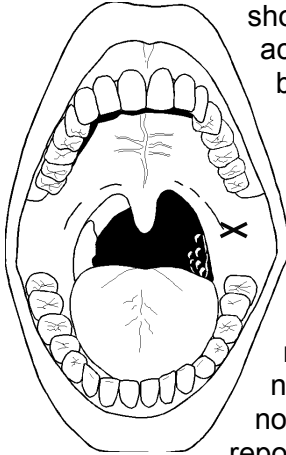


Inferior Alveolar Nerve Block

The inferior alveolar nerve block is the most commonly used injection in mandibular anesthesia. It provides anesthesia to the mandibular teeth to the midline on the side injected as well as the body of the mandible, the buccal mucosa and bone of the teeth anterior to the mandibular first molar, the anterior two thirds of the tongue and floor of the mouth, and the mucosa and bone lingual to the mandibular teeth on the side of injection. Use a 25 gauge long needle. A 27 or 30 gauge needle tends to be deflected or bent by the tissues and the anesthetic

may end up being deposited off target. Patients have not demonstrated an ability to differentiate between a 25 or 30 gauge needle.

The tissue should be penetrated at the medial border of the mandibular ramus at the height of the coronoid notch at the pterygomandibular raphe. The puncture point should be about 1.5 cm above the mandibular occlusal plane with the bevel toward the bone. The barrel of the needle



should be parallel with the occlusal plane of the mandibular molars, and come across the premolars of the opposite quadrant. Approximate the posterior border of the ramus by observing the most distal area of the pterygomandibular raphe as it turns up toward the palate. The needle insertion point is on the line of the coronoid notch and about three-fourths the distance from the ramal border. The needle should be advanced slowly, depositing a few drops of anesthetic and aspirating, until bone is contacted. Usually in an adult patient, the needle will be inserted 20 to 25 mm (about 2/3 the length of the needle). The anesthetic will be delivered directly above the mandibular foramen. If the bone is contacted at 1/2 needle depth or less, withdraw slightly and reposition the barrel of the needle over the canine or lateral incisor of the opposite quadrant. If bone is not contacted the needle is too far posterior and the barrel should be repositioned over the first molar of the opposite quadrant. After bone has been

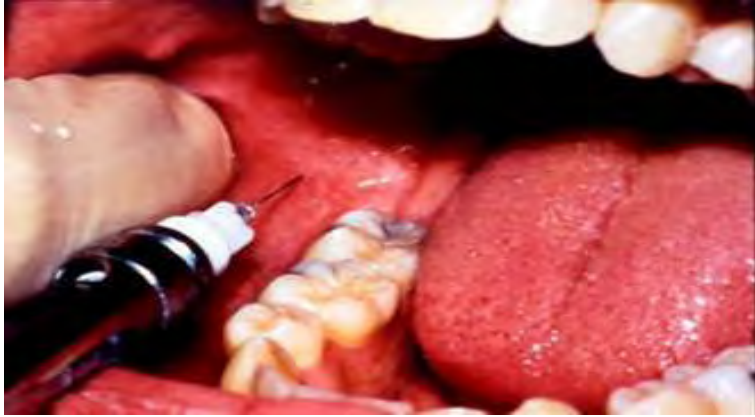contacted, withdraw the needle 1 mm and aspirate. If negative, slowly deposit 1/4 cartridge and reaspirate. If still negative, continue the process of slow deposition and aspiration until 1.5 ml of anesthetic has been delivered to the site. Withdraw the needle to about 1/2 of its length and reaspirate. If negative, deposit the remainder of the anesthetic in the cartridge for the lingual nerve.

The most common problems leading to failure in achieving anesthesia of the inferior alveolar nerve include:

Problem	Suggestion
Anesthetic is deposited below the mandibular foramen.	Reinject at a higher site.
Anesthetic is deposited too far anteriorly on the ramus.	Reinject with the needle tip more posterior.
Needle deflected by tissue, anesthetic deposited to the left or right of the foramen.	Use a 25 gauge long needle.
Anesthetic doesn't reach the nerve.	Use an anesthetic without vasoconstrictor for second injection to allow for diffusion. Remember, this anesthetic effect will not last as long.
There may be accessory nerves supplying the mandibular teeth.	Reinject distal lingual to the tooth not anesthetized at the lingual border of the mandible or use a periodontal ligament injection.

Buccal Nerve Block

The buccal nerve is not anesthetized by an inferior alveolar nerve block. This nerve innervates the tissues and periosteum buccal to the molars, so if these soft tissues are involved in treatment, the buccal nerve should be injected as well. The additional injection is unnecessary when treating only the teeth. A 25 gauge long needle is recommended (because the injection usually follows an inferior alveolar nerve block, so the same needle can be used after more anesthetic is loaded). The needle is inserted in the mucous membrane distal buccal to the last



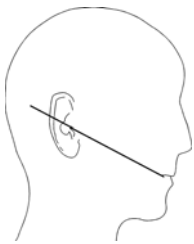
molar with the bevel of the needle facing towards the bone after the tissue has been prepared with antiseptic and topical. If tissues are pulled taut, the injection is more comfortable for the patient. Insert the needle to 2 to 4 mm to gently contact bone, and aspirate. If negative, slowly deposit about 1/8 of the solution in the cartridge.

Other Mandibular Nerve Block

Anesthetic Techniques

Two mandibular block techniques were introduced in the 1970's. The Gow-Gates mandibular block and the Akinosi closed mouth mandibular block now are accepted techniques for mandibular anesthesia, especially when the standard inferior alveolar nerve block fails to supply adequate anesthetic effect.

The Gow-Gates Technique



The Gow-Gates Block is an effective technique for mandibular anesthesia for an experienced practitioner. If the practitioner has any doubts about the technique, a hands-on course at a local dental school is recommended. The needle is inserted higher, and a practitioner who is accustomed to the inferior alveolar nerve block as the only mandibular block may be very uncomfortable with it. As with so many other things, experience is the best teacher, and once learned, the Gow-Gates block can be used on all patients with the same confidence as other techniques. The technique will anesthetize the mandibular teeth to the midline, the buccal tissues and bone, the floor of the mouth and tongue to the midline, lingual tissues and bone, the body of the mandible, and

the skin over the zygoma. This is the ideal injection to use for quadrant dentistry or when the inferior alveolar nerve block fails. Many practitioners use this technique as the block of choice because it only requires one injection.

Use a 25 gauge needle and prepare the injection site with antiseptic and topical in the mucous membrane on the mesial of the ramus, on an imaginary line from the intertragic notch to the corner of the mouth, distal to the maxillary second molar. If there is a third molar present, the penetration should be just distal to it. The height of the injection is just below the mesiolingual cusp of the maxillary second molar. Tissues are retracted with the opposite hand at the coronoid notch.

Keep the barrel of the needle approximately over the mandibular premolars and insert the needle using the landmarks of the tragus and second molar mentioned above. Keep the needle parallel with the imaginary line from the corner of the mouth and the intertragic notch and advance the needle slowly until bone is contacted. This will be the neck of the condyle. Insertion

depth is approximately the same as for the inferior alveolar nerve block - about 25 mm in an adult. If bone is not contacted, slightly withdraw the needle and reinsert. The tissues of this area may deflect the needle off target. Once the needle contacts bone, withdraw it about 1 mm and aspirate. Positive aspiration for this injection occurs less often than for others (less than 2%), but aspiration is still necessary. If positive, the needle is probably in the internal maxillary artery, inferior to the target. Withdraw the needle, change cartridges, and redirect the needle superiorly to the previous injection site. If negative, slowly deposit a cartridge using the same safety technique of aspiration and deposition as mentioned earlier. After the needle is withdrawn, instruct the patient to keep their mouth open for a few minutes for the anesthetic to properly diffuse. Onset of anesthesia may take longer because the nerve is denser at this point and the area of deposition is somewhat farther from the nerve. The patient's tongue and lower lip should be numb, check all areas for anesthesia before proceeding with treatment.

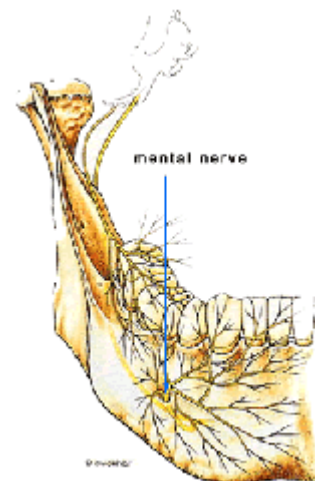
Akinosi Closed Mouth Technique

The Akinosi closed-mouth mandibular block is used especially when the patient has limited mandibular opening, but can be used routinely for mandibular anesthesia. It anesthetizes the mandibular teeth to the midline, the body of the mandible and part of the ramus, buccal tissues and bone anterior to the mental foramen, the tongue and floor of the mouth, and the lingual tissues and bone. Use a 25 gauge long needle with the bevel oriented away from the mandibular ramus. After preparing the tissue with antiseptic and topical, insert the needle in the soft tissue over the medial border of the mandibular ramus adjacent to the maxillary tuberosity in the mucogingival junction by the third molar, not as high as the Gow-Gates block but higher than the inferior alveolar nerve block. Needle insertion is mesial to the ramus, but lateral to the tuberosity. The barrel of the needle is parallel with the occlusal plane. Advance the needle to approximately 25 mm for an adult. The tip of the needle should be in the middle of the pterygomandibular space, not contacting bone. After negative aspiration, deposit 3/4 to 2/3 cartridge (slowly with more aspirations, as mentioned previously). Seat the patient upright so the solution will diffuse to the proper area. Motor nerve paralysis should result allowing the patient suffering from trismus to open freely. If there is not enough anesthesia for treatment, a Gow-Gates block or other standard injections can now be performed.

Mental Nerve Block

The mental nerve innervates the soft tissues anterior to the foramen, which is usually located at the apices of the premolars. It does not anesthetize the teeth. This technique is useful for curettage or biopsy.

When a maxillary or inferior alveolar nerve block is successful, there should be no need for this injection. A 25 gauge short needle is inserted (after proper tissue preparation with antiseptic and topical) in the mucobuccal fold near the mental foramen with the bevel of the needle oriented toward the bone. The foramen can be palpated or is visible on x-rays and is usually near the apices of the premolars. The patient may feel soreness when the nerve is palpated in the foramen. About one third cartridge should be slowly injected after negative aspiration.



Incisive Nerve Block

The incisive nerve innervates the lower teeth anterior to the mental foramen to the midline. The anesthetic solution should be deposited in the same area as the mental block, but the incisive nerve runs inside the foramen, so the needle is directed into the foramen. The anesthetic must diffuse into the foramen to affect the incisive nerve. Pressure applied to the injection site after needle withdrawal may help to guide the solution into the foramen.

Periodontal Ligament Injection

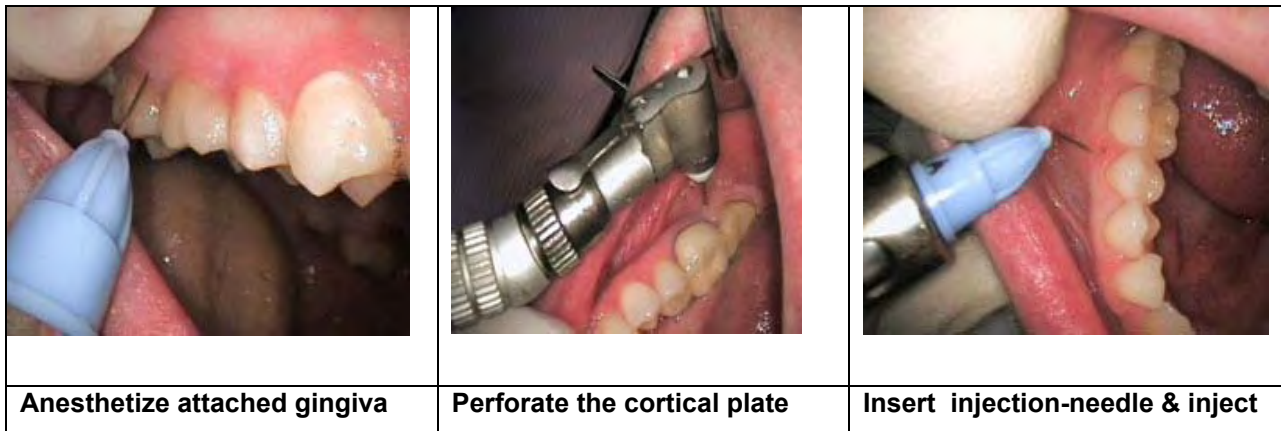
All techniques previously described anesthetize regions of the mandible. When only a single tooth is to be treated, the practitioner has the option to selectively anesthetize the tooth and its surrounding tissues without involving the other teeth, tongue, and lip. Periodontal ligament injections can be useful for maxillary as well as mandibular teeth, but is more often used in the mandible because the bone is too dense for good diffusion of anesthetic with a supraperiosteal injection. This technique can provide anesthesia for the tooth, bone, soft tissue, apex, and pulpal tissues in the area of injection. The technique can also be used as an adjunct to other blocks that are only partially successful. Special syringes are available to make the injection easier to administer, but a standard syringe will deliver the solution just as well. The syringes designed specifically for this technique tend to give the operator more force in the injection, and a standard syringe is more controllable. The solution diffuses apically through marrow spaces in the intraseptal bone. If the solution is injected too quickly into the tissue, the patient may have postoperative discomfort. Prepare the site of injection with antiseptic and topical. Since the needle is inserted in the sulcus, the topical may not be as effective. Use a 27 gauge short needle (30 gauge tends to bend too easily) and insert it into the gingival sulcus of the tooth to be anesthetized. In some posterior regions it may be necessary to bend the needle to gain access to the area. The barrel of the syringe should be parallel with the long axis of the tooth. The needle is advanced apically until resistance is met. Slowly deposit 0.2 ml of solution. (The rubber stopper is equal to 0.2 ml of solution, so it can be used as a gauge) Significant resistance to the deposition of solution is usually felt when the needle is in the correct position. The solution must not escape back up the sulcus into the patient's mouth. The full 0.2 ml must diffuse into the tissues. The procedure should be performed for all roots of the tooth. (Multirrooted teeth receive 0.2 ml of solution per root.) Duration of anesthesia is variable.

Intraseptal Injection

The intraseptal injection is used for hemostasis, soft tissue anesthesia, and osseous anesthesia. Prepare the tissues of the site with antiseptic and topical. Use a 27 gauge short needle and insert it into the papilla of the area to be anesthetized at an angle of 90° to the tissue. Slowly deposit 0.2 ml of solution.

Intraosseous Injection

Anesthetic deposited into the local tissues is effected by the conditions present in the tissue. When the anesthetic is injected in the bone through a hole in the cortical plate, the tissue will not affect it, and it anesthetizes only the area of treatment, not the quadrant. Topical anesthetic is applied first and a small amount of anesthetic is injected into the mucous membrane in the area to be perforated. A perforator attached to the high speed drill (available commercially) bores a hole of 0.43 mm. through the cortical plate. A needle of 0.4 mm. (27 gauge) is inserted into the hole and less than 1 cartridge of anesthetic is delivered into the hole. One cartridge of anesthetic is the maximum per visit using this technique. The needle must be placed in the prepared hole at the same angulation and depth or the anesthetic will leak out with no resulting anesthesia. A hands-on course is recommended for this technique. Improper angulation of the perforator can pierce a root.



Onset of anesthesia is quick (30 seconds) and profound without numbing the tongue and lips. This will allow for restorative work to begin almost immediately after injection and bilateral mandibular anesthesia can be achieved. No palatal injection is required for maxillary anesthesia. Patients report the injection is painless and less time is spent waiting for anesthesia.

Endodontically Involved Teeth

Infection at the apex of an endodontically involved tooth lowers the pH of the area and the anesthetic is neutralized and rendered less effective. The low pH in the extracellular space reduces the proportion of anesthetic in the lipophilic, free base form and reduces the anesthetic's ability to cross the nerve sheath and membrane. The anesthetic should be deposited away from the area of infection, further up the nerve where the pH is normal. Infiltration injection is usually reliable if there is no infection present. A regional nerve block should be used if abscess is present. An intrapulpal injection can be used when the pulp chamber has been exposed. Use a 25 gauge needle, (bent if necessary) and insert it into the pulp chamber firmly. Deposit the solution with pressure. A periodontal ligament injection can be used as an adjunct procedure to make anesthesia more profound. An intraosseous injection may allow access to the pulp chamber. The area is anesthetized with an infiltration injection, then an incision is made at the apex of the tooth to be treated. A small bur is used to open the cortical plate to the cancellous bone. Approximately 1 ml of solution is injected into this hole. It is recommended that if a solution containing vasoconstrictor is used, it should not exceed 1:100,000 in concentration. If the tooth cannot be anesthetized until the pulp chamber is exposed, a low-speed high-torque instrument should be used. Nitrous oxide or conscious sedation may be considered as adjuncts during endodontic procedures if anesthesia is difficult to achieve. Once the pulp chamber is opened, the intrapulpal injection will usually be effective. If the pulp is still sensitive, place an anesthetic-soaked cotton pellet in the chamber. After a few

seconds, press the pellet down more firmly. Within a few minutes, an intrapulpal injection should be effective. After the pulp has been removed, the area is much easier to anesthetize.

Complications

Pain on Injection

An injection technique that is too rough, a dull needle, rapid deposition of solution, or a barb on the needle can cause pain. Confident and compassionate practitioners can deliver dental anesthesia with little to no discomfort. If a needle is used for more than 3 penetrations or if it comes into contact with bone, check it for barbs and dullness and change it if necessary.



A mild burning sensation during administration may be due to the pH of the solution, contamination of the local anesthetic, or a solution that has been warmed too much. The mild burning of the acidic local anesthetic solution is unavoidable, and will dissipate as the anesthetic takes effect. If the cartridge is soaked in solutions, the semipermeable membrane will allow diffusion into the anesthetic. Contaminated solution can lead to trismus or infection.

Paresthesia

If the needle passes through a nerve in the area of injection, it may damage the nerve and cause paresthesia. The injury is usually not long term or permanent. Make a note in the chart if the patient reports a shooting feeling during the injection that would indicate needle contact with the nerve. A local anesthetic that has been contaminated by alcohol or a sterilizing solution may cause tissue irritation and edema, which will in turn constrict the nerve and lead to paresthesia. Proper injection protocol and care of the dental cartridges will reduce the incidence of paresthesia, but it can still occur.

If the patient calls reporting paresthesia, explain to them that it is not an uncommon result of an injection and make an appointment for examination. Make a note of the conversation in the patient's chart. The condition may resolve itself within 2 months without treatment. Examine the patient and schedule them for reexamination every 2 months until sensation returns. If the paresthesia continues after one year, refer the patient to a neurologist or oral surgeon for a consultation. If further dental treatment is required in the area, use an alternate local anesthetic technique to avoid further trauma to the nerve.

Hematoma

The needle can nick vessels as it passes through highly vascular tissues. A nicked artery will usually result in a rapid hematoma, while a nicked vein may or may not result in a hematoma.

Hematomas most often occur during a posterior superior alveolar or inferior alveolar nerve blocks. Use a short needle for the PSA and be conscious of depth of penetration for these injections.

If the hematoma develops during an inferior alveolar nerve block, apply pressure to the medial aspect of the mandibular ramus. The manifestations will usually be intraoral. If the hematoma develops during an infraorbital nerve block, apply pressure to the skin directly over the infraorbital foramen. The discoloration will be below the lower eyelid. Hematomas do not usually develop in this injection because the technique requires pressure to the injection site during and directly after the injection. If the hematoma develops during a mental or incisive nerve block apply pressure over the mental foramen. The skin will discolor over the mental foramen and swelling will occur in the mucobuccal fold. If the hematoma occurs during a posterior superior

alveolar nerve block, the blood will diffuse into the infratemporal fossa, and swelling will appear on the side of the face just after the injection is completed. The swelling occurs after a significant amount of blood has diffused, so direct pressure is often useless. Apply external ice.

Make a note of the hematoma on the patient's chart and advise them of possible soreness. If soreness develops, prescribe analgesics, but do not apply heat to the area for at least 4 to 6 hours. Heat therapy may begin the following day.

The hematoma will disperse within 7 to 14 days with or without treatment. Avoid dental therapy in the area until the tissue is healed.

Trismus

Trismus is a motor disturbance of the trigeminal nerve and results in a spasm of the masticatory muscles causing difficulty in opening the mouth. Trismus can be caused by trauma to muscles or blood vessels in the infratemporal fossa, injection of alcohol or sterilizing solution contaminated local anesthetic causing irritation to the tissues, hemorrhage, large volumes of anesthetic solution deposited in one area, or infection. If not treated, a chronic phase may develop leading to hypomobility, fibrosis, and scarring.

Use of disposable needles, antiseptic cleansing of the injection site, aseptic technique, and atraumatic injection technique will help prevent trismus.

Recommended treatment for trismus includes heat therapy with moist hot towels 20 minutes every hour, analgesics, and muscle relaxants if necessary. The patient should be instructed to exercise the area by opening, closing, and lateral excursions of the mandible for 5 minutes every 3 to 4 hours. The patient can chew sugarless gum to facilitate lateral movement of the TMJ.

Record the incident and findings in the patient's chart. Avoid treatment in the area until symptoms resolve. If treatment is unavoidable, employ an Akinosi mandibular nerve block to loosen the motor nerves of the area and use an alternative method of anesthesia to avoid further injury to the motor nerve.


Continue therapy until the patient has no symptoms. If the pain continues over 48 hours, an infection may be present. Antibiotic therapy for 7 full days is indicated. If there is no improvement after 2 to 3 days without antibiotics or 7 to 10 days with antibiotics, refer the patient to an oral surgeon for evaluation.

Infection

Infection from a dental injection has become rare due to the use of sterile disposable needles and one-patient use cartridges. The needle will always be contaminated when it comes in contact with the patient's mucosa. Proper tissue preparation and sterile technique will virtually eliminate infection at the injection site.

If the patient reports post injection pain and dysfunction one or more days following treatment, manage as with trismus. If the symptoms do not resolve within three days, prescribe a seven day course of antibiotic therapy. (Usually 500 mg. penicillin V immediately then 250 mg. four times a day or erythromycin if the patient is allergic to penicillin.) Record the incident and treatment in the patient's chart.

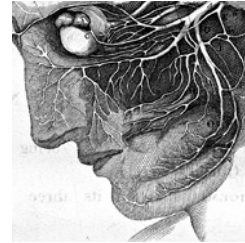
Double and Blurred Vision



If the anesthetic solution is deposited too near the inferior rectus muscle or the sympathetic innervation to the eye, it can anesthetize the eye. This is a temporary condition and self-limiting. Patch the patient's eye until vision returns to normal.

Facial Nerve Paralysis

If the local is injected into the parotid gland, it will affect the facial nerve and the patient will notice facial drooping and will not be able to close their eye. If the needle is directed too posteriorly during an inferior alveolar nerve block or is over inserted during an Akinosi nerve block, the parotid gland may be anesthetized. Bone should be contacted before deposition of solution in the inferior alveolar nerve block to make sure the tip of the needle is not in the parotid gland. Inferior alveolar nerve anesthesia will not develop if the solution is in the parotid gland.



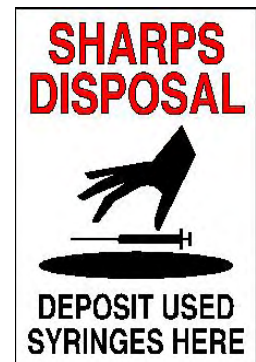
This is also self-limiting, and symptoms will diminish as the anesthetic effect wears off. The tear ducts in the eye will still function, but remove a contact lens if present. Explain the situation to the patient and give them the option of reinjecting and continuing treatment or postponing treatment until another day.

Broken Needles

The most common cause of needle breakage is sudden unexpected movement of the patient. Smaller gauge needles (size 30) are more likely to break than larger ones (size 25). Some practitioners habitually bend the needle and the metal is weakened in this area. A needle that breaks with part of it visible can be easily removed with a hemostat. Needles that break within the tissue may require removal by surgery.

The best way to avoid needle breakage is to routinely use a 25-gauge needle for any injection where there is a significant penetration of tissue. The hub is the weakest part of a needle, so unless the injection technique specifically requires it, the needle should not be inserted all the way to the hub. A longer needle should be used.

When a needle breaks, remain calm. Instruct the patient to keep their mouth open, and if at all possible, place a biteblock. If an end of the needle is visible, retrieve it with a hemostat or cotton pliers. If it is not visible, do not try to retrieve it at this time. Explain to the patient what has happened. Make a note in the patient's chart about the incident. Inform your insurance carrier immediately. Send the patient to an oral surgeon for consultation. They may surgically remove the fragment or if the procedure will cause too much damage they may leave it where it is.



Other Methods of Anesthesia

Electronic Dental Anesthesia

The medical profession has been recognizing the validity of using electricity in the management of pain since the early 1960's. Transcutaneous electrical nerve stimulation (TENS) has been used for management of chronic and acute pain as well as some areas of sports medicine.



Comfort Control™ Syringe

Theories on the mechanism of action of electrical stimulation of the nerve for pain control are many. One involves the release of endorphins and enkephalins after prolonged (over 10 minutes) exposure to electrical stimulation. Another postulates quicker healing may be aided by the muscle contraction and vasodilation provided during electric stimulation.

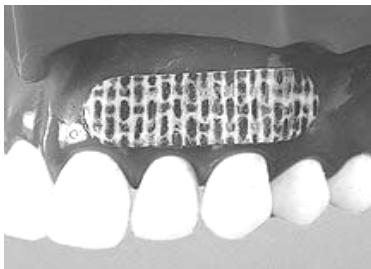Recently, interest has surfaced over the TENS unit modified for dental use. A hands-on continuing education course in electronic dental anesthesia is recommended for any dental professional seriously considering application of this technique in daily practice. Successful technique is best learned in the controlled atmosphere of a class rather than experimentation during clinical practice.

Research supports the success rate of electronic dental anesthesia in restorative dentistry, nonsurgical periodontics, extractions, TMJ therapy, and MPD therapy. It has proved especially successful in conjunction with nitrous oxide-oxygen inhalation conscious sedation.

In many instances, proper use of electronic dental anesthesia results in the lack of need for local anesthetic and provides painless injections when used before administration. The patient controls the level of anesthesia needed, and once the unit is turned off, there is no numbness to recover from as with local.

Patients with pacemakers, neurophysiological disorders (like epilepsy) and pregnant women should not be offered electronic dental anesthesia because of potentially harmful side effects.

Lidocaine Patch



Noven Pharmaceuticals has released a product called the DentiPatch™. It is an adhesive containing 46.1 mg of lidocaine. The lidocaine is absorbed by the mucosa, and they claim anesthetic onset within 2.5 minutes of application. The patch is left in place up to 15 minutes and the anesthetic effect can last up to 30 minutes after removal. The total amount of drug absorbed during the 15 minutes of application is confined to the fixed surface levels. Blood levels of lidocaine following application are less than 0.1 µg/mL. Clinical studies indicated

that it provides a significant decrease in pain scores as compared to a placebo.

The FDA approved the DentiPatch in 1996. It is indicated for use when mild topical anesthesia is desired for superficial dental procedures or prior to local anesthetic injection.

An article by Elliot Hersch et al. in the Journal of the American Dental Association (Nov. 1996) evaluated the efficacy and safety of intraoral lidocaine patches. They concluded that "lidocaine patches achieved significantly better analgesia than a placebo within two and a half to five minutes after placement." They found that "side effects were minimal and venous blood levels of lidocaine were low, averaging 10 to 14 times less than those achieved with a

typical injection of lidocaine with epinephrine.... The lidocaine patches used in this study are effective and safe in reducing needle insertion pain in adults.”

Please mark only one **best** answer to the following questions on the one page answer sheet. This test contains 25 questions. Please mark your answers in spaces numbered 1 through 25 on your answer sheet.

1. Afferent or sensory nerves conduct impulses to the
 - a. CNS.
 - b. periphery of the body.
 - c. motor nerves of muscles.
 - d. pain stimulus.

2. Efferent or motor neurons conduct messages from
 - a. the periphery of the body to the CNS.
 - b. the pain stimulus to the periphery.
 - c. the CNS to the periphery.
 - d. the cell body to the CNS.

3. The most widely held theory on nerve transmission attributes conduction of the nerve impulse to changes in the
 - a. axoplasm.
 - b. axolemma.
 - c. cell body.
 - d. CNS.

4. For a local anesthetic to be clinically useful,
 - a. it should be compatible with the tissues (not irritating)
 - b. it's action should be temporary.
 - c. it's action should be completely reversible.
 - d. all of the above.

5. Amide anesthetics include:
 - a. lidocaine
 - b. cocaine
 - c. novocaine
 - d. procaine

6. Ester anesthetics include:
 - a. mepivacaine (or carbocaine)
 - b. prilocaine (or citanest)
 - c. procaine
 - d. bupivacaine (or marcaine)

7. Local anesthetics interfere with how the impulses travel down the length of the nerve.
- True
 - False
8. Anesthetics are not as effective when infection is present because the pH of the tissues is to allow the anesthetic to penetrate the nerve sufficiently.
- too high
 - too low
9. A local anesthetic that is absorbed by the bloodstream is carried to
- all the tissues of the body.
 - some of the fat tissues of the body.
 - the urinary tract only.
 - the brain only.
10. Highly _____ organs like the brain, liver, lungs, and kidneys will have higher blood levels of anesthetic following injection than other less _____ areas.
- innervated
 - toxic
 - vascular
 - complex
11. Vasoconstrictors are added to local anesthetics to _____ the absorption of the drug and prolong the anesthetic effect.
- decrease
 - increase
 - stop
 - facilitate
12. Epinephrine is contraindicated in patients with:
- blood pressure over 200 systolic or 115 diastolic,
 - uncontrolled hyperthyroidism,
 - severe cardiovascular disease including less than 6 months after a myocardial infarction
or cerebrovascular accident
 - daily episodes of angina pectoris or unstable angina
 - all of the above
13. A factor that influences the action of local anesthetics is:
- the patient's individual response to the anesthetic.
 - anxiety
 - the type of syringe used.
 - a and b.
14. Lidocaine 2% with epinephrine 1:100,000 will provide pulpal anesthesia for approximately
- 3 hours
 - 60 minutes
 - 10 minutes
 - 2 hours

15. Topical anesthetic is effective only about 2-3 mm of depth into the tissues on which it is applied.
- True
 - False
16. When administering lidocaine 2% to a 180 lb. patient, the maximum amount recommended is:
- 300 mg
 - 500 mg
 - 700 mg
 - 100 mg
17. The most likely place for a needle to break is
- at the bevel
 - at the tip
 - in the middle
 - at the hub
18. Dental cartridges should be:
- submerged in alcohol.
 - submerged in cold sterile solution.
 - left overnight in a cartridge warmer.
 - kept dry.
19. If a patient's blood pressure is 205/110, consult with their physician before administering local anesthetic.
- True
 - False
20. The patient's baseline vital signs including _____ should be taken and recorded in the patient's chart before the injection of local anesthetic.
- blood pressure
 - heart rate
 - respiration rate
 - all of the above
21. Pain on injection can be caused by
- an injection technique that is too rough.
 - a dull needle.
 - rapid deposition of solution.
 - a barb on the needle.
 - any of the above.
22. Hematomas most often occur during a
- posterior superior alveolar nerve block.
 - palatal injection.
 - maxillary nerve block.
 - periodontal ligament injection.

23. Recommended treatment for trismus includes
- a. heat therapy with moist hot towels 20 minutes every hour
 - b. analgesics
 - c. muscle relaxants if necessary.
 - d. all of the above.
24. Facial nerve paralysis may result from anesthetic being injected
- a. into a vessel.
 - b. into a nerve.
 - c. into the parotid gland.
 - d. into the pulp of a tooth.
25. The most common cause of needle breakage is
- a. sudden movement by the patient.
 - b. bowing of the needle during injection.
 - c. autoclaving the needle.
 - d. incorrect recapping technique.

(end of test)